

Paweł Daszkiewicz¹, Zuzanna Daszkiewicz², Piotr Daszkiewicz³, Tomasz Wojtas⁴

Arachnoid cyst of lateral fissure: an old problem revisited. Suggestion of a novel approach based on own material

Torbiel pajęczynówki bruzdy bocznej mózgu: nowe spojrzenie na stary problem.

Sugestia nowego podejścia do leczenia na podstawie materiału własnego

¹ Department of Neurosurgery, The Children's Memorial Health Institute, Warsaw, Poland

² Student; Warsaw Medical University, Poland

³ General Medical Practice "Poradnia Lekarza POZ," Żąbki, Poland

⁴ Institute "Centrum Pediatrii," Sosnowiec, Poland

Correspondence: Paweł Daszkiewicz, Department of Neurosurgery, The Children's Memorial Health Institute, Dzieci Polskich 20, 04-730 Warsaw, Poland, tel.: +48 22 815 75 60, e-mail: pmdaszkiewicz@o2.pl
Paweł Daszkiewicz, Klinika Neurochirurgii, Instytut „Pomnik – Centrum Zdrowia Dziecka”, al. Dzieci Polskich 20, 04-730 Warszawa, tel.: +48 22 815 75 60, e-mail: pmdaszkiewicz@o2.pl

Abstract

Introduction: Arachnoid cysts located in the middle cranial fossa still poses a clinical challenge and requires a staged approach. Accepted procedures include modalities differing in mechanism of action, i.e. communication of the arachnoid cyst with arachnoid cisterns by endoscopy or craniotomy (internal decompression) and placement of a shunt (external decompression). Therefore, arachnoid cysts may in fact represent a group of diseases with different underlying pathology. **Material and methods:** Between January 1980 and December 2017, a total of 276 patients were operated on for an arachnoid cyst of lateral fissure. Mean age was 6.5 years and mean follow-up time was 9.7 years. A retrospective analysis of medical records was performed. Statistical analysis was performed using the Chi-squared test with Yates' correction. **Results:** A single surgical procedure was performed in 89% of patients (simple arachnoid cysts, SAC), whereas 2–4 procedures were needed in 11% of cases (complex arachnoid cysts, CAC). In the CAC group, internal and external decompression was effective in 20% and 80% of the cases, respectively. In the SAC group, the proportions were nearly exactly opposite (71.9% and 19.9%, respectively) ($p < 0.001$). A low-pressure cystoperitoneal shunt proved effective only in 4/30 patients (13%), the remaining patients required a switch to medium- or high-pressure shunt. **Conclusions:** 1) A small proportion of children with an arachnoid cyst have a coexisting cerebrospinal fluid absorption deficit. 2) In these cases, effective treatment consisted in placement of a medium- or high pressure shunt; low-pressure shunts produced symptomatic overdrainage. 3) Risk factors for this subgroup of patients are: younger age, epilepsy, ventriculomegaly and cyst mass effect at presentation.

Keywords: arachnoid cyst, hydrocephalus, treatment, children

Streszczenie

Wprowadzenie: Torbiele pajęczynówki zlokalizowane w środkowym dole czaszki wciąż stanowią istotny problem kliniczny i niekiedy wymagają wieloetapowego leczenia. Ogólnie przyjęte sposoby postępowania obejmują zabiegi o zasadniczo różnym mechanizmie działania, tj. połączenie torbieli ze zbiornikami pajęczynówki w wyniku operacji mózgu techniką endoskopową lub na drodze kraniotomii (odbarczenie wewnętrzne) albo implantację układu zastawkowego torbielowo-otrzewnowego (odbarczenie zewnętrzne). Z tego względu nasuwa się wniosek, że torbiele pajęczynówki mogą w rzeczywistości stanowić grupę chorób różniących się pod względem patofizjologii. **Materiał i metoda:** Od stycznia 1980 do grudnia 2017 roku w naszym ośrodku operowano 276 pacjentów z torbielą pajęczynówki bruzdy bocznej. Średnia wieku wynosiła 6,5 roku, a średni czas obserwacji – 9,7 roku. Pracę przeprowadzono metodą retrospektywnej analizy dokumentacji medycznej. W analizie statystycznej wykorzystano test Chi-kwadrat z poprawką Yatesa. **Wyniki:** 89% pacjentów operowano jeden raz, uzyskując trwałe wyleczenie (tzw. grupa torbieli prostych, *simple arachnoid cysts*, SAC), podczas gdy 11% pacjentów wymagało od 2 do 4 zabiegów (tzw. grupa torbieli złożonych, *complex arachnoid cysts*, CAC). W grupie CAC odbarczenie wewnętrzne i zewnętrzne okazało się skuteczne odpowiednio w 20% i 80%. W grupie SAC proporcje były niemal dokładnie odwrotne (odpowiednio 71,9% i 19,9%; $p < 0,001$). Zalecana w jednym z podstawowych podręczników akademickich

implantacja zastawki niskociśnieniowej okazała się skuteczna jedynie u 4/30 pacjentów (13%), wszyscy pozostali wymagali zastawek średnio- albo wysokociśnieniowych. **Wnioski:** 1) U niewielkiego odsetka dzieci z torbielą pajęczynówki współistnieje deficyt wchłaniania płynu mózgowo-rdzeniowego. 2) W tych przypadkach skuteczne leczenie wymaga implantacji układu zastawkowego średnio- albo wysokociśnieniowego, podczas gdy układy niskociśnieniowe powodowały objawowy zespół przedrenowania. 3) Czynniki ryzyka dla tej podgrupy pacjentów obejmują młodszy wiek, padaczkę, poszerzenie układu komorowego i efekt masy torbieli w chwili przyjęcia.

Słowa kluczowe: torbiel pajęczynówki, wodogłowie, leczenie, dzieci

INTRODUCTION

Although arachnoid cysts (ACs) have already been extensively studied, certain aspects of their pathophysiology are still poorly understood. Symptom control not infrequently necessitates multiple procedures significantly differing in the mechanism of action, suggesting that ACs may in fact represent a group of conditions differing in terms of underlying pathology and optimal management.

This paper deals exclusively with ACs located in the middle cranial fossa.

AIM OF THE PAPER

The aim of this paper was to analyse outcomes in children diagnosed with an AC over the past 35 years treated at a single centre, using the same protocol and surgical technique, to elucidate some aspects of AC pathophysiology, possibly to select distinct subgroups of patients and optimise treatment protocols.

MATERIAL AND METHODS

Between January 1980 and December 2017, a total of 276 patients (age range 6 months – 18 years; mean: 6.5 years) were received surgical treatment due to an AC. Indications for surgical treatment were clinical symptoms concordant with imaging studies revealing an AC Galassi grade II or III (Galassi et al., 1982). Since contrast cisternography was not performed routinely, communication (or its absence) of AC with basal arachnoid cisterns could be deduced based on the presence (or absence) of mass effect and correlation between the size of ventricles and cyst.

Surgical treatment included communication of the cyst with basal arachnoid cisterns (by endoscopy or craniotomy) or evacuation of cyst fluid by cystoperitoneal or subduroperitoneal shunt (Strojnik, 2006). In cases presenting with acute or subacute subdural haematoma, a temporary subdural external drainage was used. Endoscopic fenestration, open craniotomy, drainage and shunt placement were performed under general anaesthesia, using standard and generally accepted techniques. Depending on individual anatomy, ACs were communicated with as many cisterns as was safely possible (chiasmatic, basal, internal carotid). Long-standing compression by the AC, adhesions

and distortion of local anatomy resulted in technical problems, which were (in our opinion) most pronounced in the endoscopic setting.

Patients underwent periodic follow-up, consisting in clinical examination, imaging studies (computed tomography or magnetic resonance imaging), ophthalmologic and psychological testing after 3, 6, and 12 months after surgery or when needed, depending on their clinical status.

This was a single-centre retrospective study, ensuring a uniform diagnostic and therapeutic approach. However, over 35 years of data collection, certain modifications resulting from general progress in medical science and accumulated experience were unavoidable. Mean follow-up time for the entire study population was 9.7 years. Statistical analysis was performed using the Chi-squared test for given probabilities with Yates' continuity correction.

RESULTS

The group ($N = 276$; 100%) included 188 males and 88 females (ratio: 2.04:1) ($p < 0.001$). A one-time surgery was performed in 246 patients (89%), achieving permanent resolution of symptoms (simple arachnoid cyst subgroup, SAC), while 30 patients (11%) required 2, 3 or 4 procedures to achieve a cure (complex arachnoid cyst subgroup, CAC).

The SAC subgroup ($n = 246$) included 173 boys and 73 girls (ratio: 2.36:1), and the CAS subgroup included 20 boys and 10 girls (ratio: 2:1) (a more pronounced male predominance in the former; a non-significant difference). Mean age at admission was 6.6 years in the SAC group vs. 5.5 years in the CAS group (a non-significant difference), indicating a somewhat earlier onset of symptoms and a more aggressive course of disease in the latter. Age distribution of patients in both subgroups is presented in Fig. 1. There is a slight predominance of children under 3 years in the SAC group, while age distribution in the CAC subgroup is more uniform with three small peaks corresponding to age 0–2 years, 5–6 years and 10–13 years.

Predominant symptoms at admission were similar in both subgroups and included headache and bulging of cranial vault in the temporal area. Epilepsy was present in 8/30 children in the CAC group (26%) and 6/246 children (2.4%) in the SAC group ($p = 0.05$).

Imaging studies in the SAC and CAS subgroups revealed a mass effect in 145/246 cases (58.9%) vs. 15/30 cases (50%)

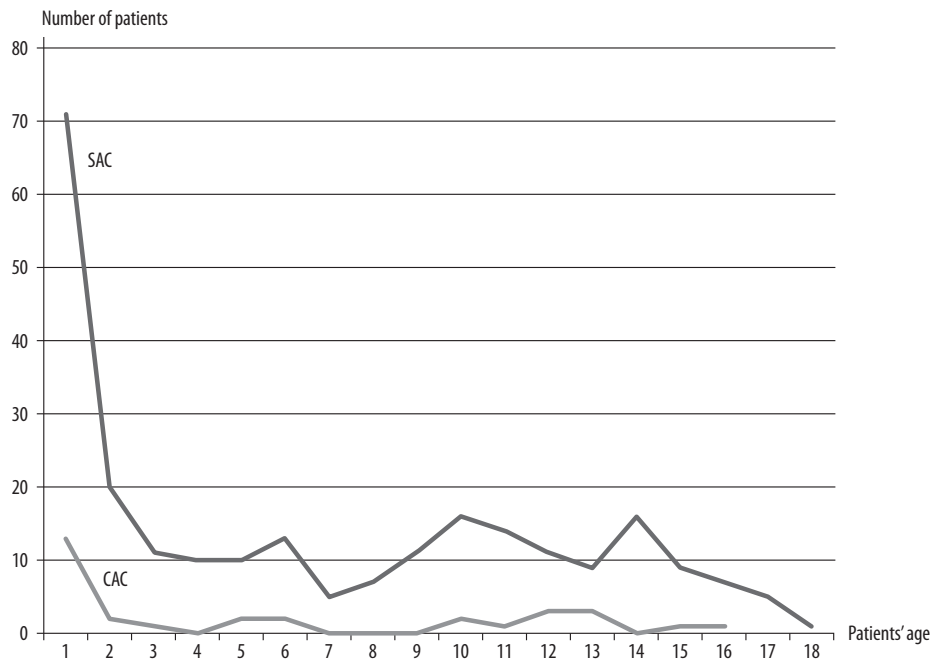


Fig. 1. Age distribution of patients in study subgroups

(a non-significant difference), respectively. Dilatation of cerebral ventricles in SAC and CAC subgroups was present in 15/246 cases (6%) and 4/30 cases (13.3%), respectively, while active hydrocephalus was seen only in 3/30 cases (10%) in the CAC subgroup only (probably due to the small number of patients, differences did not reach statistical significance; $p = 0.36$). Cerebral ventricles were essentially normal in 94% vs. 76.6% of patients in the SAC and CAC subgroups, respectively (a non-significant difference). **Treatment modalities** implemented over consecutive decades (1980–1990, 1991–2000, 2001–2010, 2011–2017) are presented in Tab. 1.

Years (n = total number of procedures)	Type of surgery
1980–1990 (n = 29)	Burr hole: 12 Shunt placement: 10 Fenestration by craniotomy: 7
1991–2000 (n = 83)	Burr hole: 10 Shunt placement: 22 Fenestration by craniotomy: 24 Fenestration by endoscopy: 27
2001–2010 (n = 80)	Burr hole: 1 Shunt placement: 3 Fenestration by craniotomy: 11 Fenestration by endoscopy: 65
2011–mid-2017 (n = 111)	Burr hole: 1 Shunt placement: 14 Fenestration by craniotomy: 16 Fenestration by endoscopy: 80

Tab. 1. Types of surgery implemented in the treatment of ACs over consecutive decades

A drop in burr holes over time (from 12 to 1) is noteworthy, most probably due to a better understanding of AC pathology. Endoscopic technique was made available at our institution in 1994, enjoying a dramatic growth thereafter. Between 1990 and mid-2017, the total number of AC-related procedures increased by nearly 20%, most probably due to improved detection. There is no definite trend in shunt placement and craniotomy. No statistically significant differences were detected.

Types of surgery implemented in the SAC subgroup (n = 246), resulting in definitive cure, are shown in Tab. 2.

A for the **types of surgery implemented in the CAC subgroup** (n = 30), placement of a **low- or very-low-pressure** shunt provided definitive symptom control in 4 cases only. In the remaining 4 cases, where such a shunt has been placed initially, patients needed a switch to medium or high pressure system. In 20 cases, initially placed medium or high pressure system (with or without anti-siphon device) provided effective and permanent control of intracranial pressure. In the remaining 6 cases, where initial endoscopic

Procedures performed	n (%)
Shunt placement (external decompression)	49 (19.9)
Cyst fenestration via craniotomy + cyst fenestration via endoscopy (internal decompression)	48 + 129 (71.9)
Burr hole and temporary subdural drainage	24 (9.3%) (incl. 7 for subdural hematoma and 1 Rickham reservoir)

Tab. 2. Types of surgery implemented in the SAC subgroup

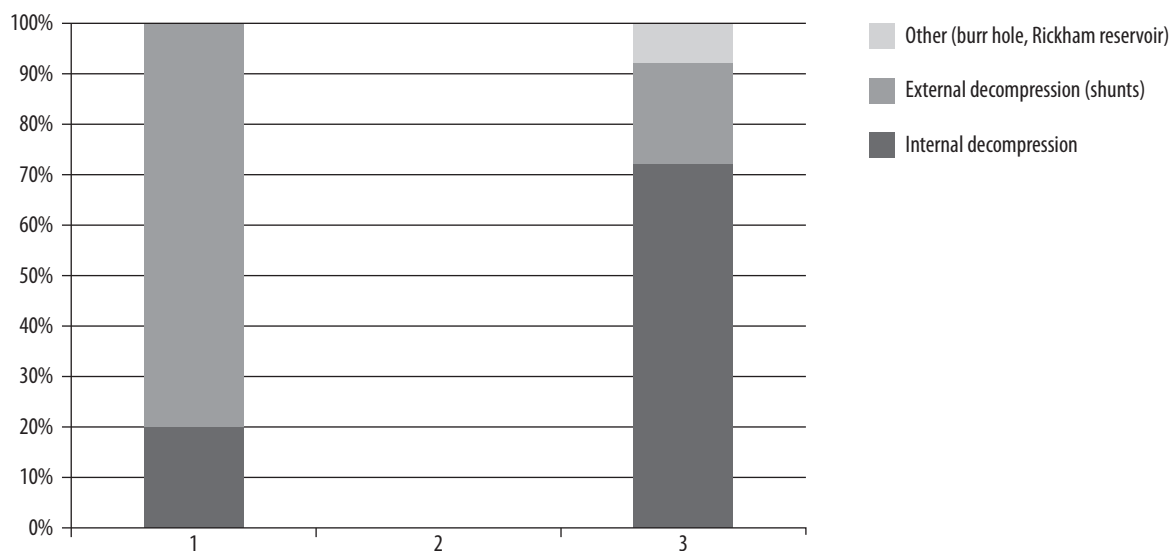


Fig. 2. Contribution of different types of definitive procedures in CAC (column 1) and SAC (column 3) subgroups

fenestration proved ineffective, craniotomy enabled effective fenestration and definitive cure. Internal decompression proved effective in 6/30 cases (20%) only; external decompression by placement of a shunting system was needed in the remaining 24 cases (80%). The proportions are nearly exactly opposite in the SAC subgroup (71.9% and 19.9%, respectively) ($p < 0.001$). These proportions are shown in Fig. 2.

DISCUSSION

Arachnoid cysts, which were first described in 1831 by Richard Bright (Wester, 2018), have been subject to extensive research ever since (Pradilla and Jallo, 2007). AC is the most common form of intracranial cystic lesion, with an incidence in general population estimated at 1.1–1.7% and a clear male predominance, which is also confirmed by our findings. Most common locations include middle cranial fossa, posterior cranial fossa and suprasellar area (Gelabert-González, 2004).

ACs may be congenital or acquired and develop as a result of abnormal splitting of outer and inner layers of the embryonal arachnoid, their traumatic rupture producing a one-way valve, or by osmotic seepage as in subdural effusions (Basaldella et al., 2007). The result is a fluid-filled cavity lined with single layer of arachnoid cells on collagen-rich stroma (Gelabert-González, 2004). Disturbed communication between AC and arachnoid cisterns was postulated already in the '80 (Galassi et al., 1982). Fluid in an AC differs from cerebrospinal fluid (CSF) by higher content of glutamate and protein (Berle et al., 2010).

Only about 20% of ACs are symptomatic, while the remaining 80% are asymptomatic and are detected incidentally (Vernooij et al., 2007; Weber and Knopf, 2006). ACs manifest usually in children and adolescents, either as mild-to-moderate recurrent headaches or sudden deterioration and

signs of increased intracranial pressure, sometimes after a mild head injury. Headache is present in 18% of patients with AC, while AC is present in only 2.6% of patients with headache (Valença et al., 2002). Other symptoms include macrocrania, bulging calvarial bones in the temporal area, hemiparesis, generalised signs of increased intracranial pressure, mental retardation and behavioural disorders (Cameron, 2002; Vakis et al., 2006). Symptoms are caused by increased pressure resulting from an enlarging cyst, development of a subdural hemato-hygroma or hydrocephalus (Stachura and Czepko, 2006).

High glutamate level, compression and coexisting focal cortical dysplasia in adjacent temporal lobe may explain high rate of epilepsy in patients with an AC. In our material, epilepsy was present in 2.4% and 26% of patients in SAC and CAC groups, respectively. While the former only slightly exceeds the known prevalence of epilepsy in general population (0.6–1%) (Fiest et al., 2017), the latter (over 20-fold higher) may indicate greater dynamics of the disease process or an entirely different underlying pathology. Literature data confirm high incidence of epilepsy and mental diseases in patients with ACs, which may be either primary (brain dysplasia causing an AC) or secondary (AC producing neurological problems) (Millichap, 1997). Sporadic elevations of intracystic/intracranial pressure might mimic epileptic attacks or psychotic phenomena, and improvement has been documented after effective treatment (Wester and Hugdahl, 1995). Permanent neurological disorders or even death associated with treatment-refractory AC have been described; therefore, even asymptomatic patients require close monitoring.

Treatment options include several modalities, of which none is considered optimal and convincingly effective, particularly in paediatric patients (Raffel and McComb, 1988). Asymptomatic cases with no mass effect (Galassi grade I and II) require conservative approach and close follow-up.

Mild-to-moderate cases require standard symptomatic management (analgesics and antiepileptics). Patients with severe clinical symptoms (ACs Galassi grade II and III) require decompression, either internal (communication of cyst with basal arachnoid cisterns by endoscopic fenestration or small pterional craniotomy) or external (placement of a cysto- or subduroperitoneal shunt) (Alexiou et al., 2010).

The crucial issue is whether there is CSF absorption deficit or not, and if so, whether the hydrocephalus is communicating or not, i.e. whether the problem is general or local. In 20–25% of the cases, AC coexists with CSF absorption deficit and communicating hydrocephalus (Helland and Wester, 2006) (in our material 11%); therefore communication of AC with arachnoid cisterns (internal decompression) will prove ineffective, as in communicating hydrocephalus. An obvious solution would be placement of a medium-pressure or programmable shunt system, which proved effective in nearly all of our problematic CAC patients. There is accumulating evidence of unfavourable effects of indiscriminate placement of shunts, particularly low-pressure ones (extreme shunt-dependency, symptomatic overdrainage syndrome, etc. (Martínez-Lage et al., 2009; Zhang et al., 2012). It should be noted that the current edition of Greenberg's *Handbook of Neurosurgery* recommends placement of a low-pressure cysto-peritoneal shunt (Greenberg, 2016). We do not agree with this approach and would strongly suggest reassessment of this point of view. Inclusion of this reference in the list is self-evident.

The high risk of shunt failures in ACs is associated with high protein content, low perfusion rate and a relatively small volume of subdural space (Alexiou et al., 2010). We try to avoid shunt placement whenever possible, and this view is generally supported in the literature (Kim et al., 2002; Martínez-Lage et al., 2009).

The choice between endoscopy and craniotomy depends on individual configuration of AC (accessibility of arachnoid cisterns), surgeon's preference and patient's choice (Raffel and McComb, 1988). Endoscopic fenestration is apparently less invasive, but provides less maneuverability at the base of the brain. Considerable failure rate of endoscopy in the treatment of ACs is well documented (Roszkowski et al., 2002). Some authors advocate placement of drains to support patency of communication, but they report poor results in terms of radiological improvement, probably due to non-effective internal decompression (Stachura and Moskała, 2009). On the contrary, craniotomy requires larger skin incision and wider bony opening, but ensures far greater maneuverability and, in our opinion, is more effective and safe (Gangemi et al., 2007). Bleeding is much easier controlled in the setting of "open" craniotomy than during endoscopy. Furthermore, in our opinion, craniotomy is much superior in terms of insight, access and scope of manoeuvres. Although we have observed no serious surgery-associated complications with either technique to date, there are reports of permanent

and severe impairment of vision, probably due to sudden decompression of optic chiasm (Puchalska-Niedbał and Jeżewski, 2007).

To conclude, our results indicate that ACs are not a homogeneous nosological entity. Two basic types of ACs may be distinguished: ACs without coexisting CSF absorption deficit (most common) and ACs with coexisting CSF absorption deficit (much less common; 11% in our material). The former requires only communication of cyst with basal arachnoid cisterns. The latter requires additional placement of a CSF-draining device (preferably a medium-pressure or programmable system).

A practical issue remains to sort-out patients at risk of CSF absorption deficit. In our material, factors heralding the need for CSF shunting were: epilepsy, ventriculomegaly, younger age and mass effect of the AC at presentation. In their absence, relying on own clinical judgment and individualised choice of therapeutic options are necessary, considering the possible necessity of multiple procedures.

CONCLUSIONS

1. A small proportion of children with an arachnoid cyst have a coexisting cerebrospinal fluid absorption deficit.
2. In these cases, effective treatment consisted in placement of a medium- or high pressure shunt; low-pressure shunts produced symptomatic overdrainage.
3. Risk factors for this subgroup of patients are: younger age, epilepsy, ventriculomegaly and cyst mass effect at presentation.

Conflict of interest

The authors do not report any financial or personal bonds with other persons or organisations, that might have a negative impact on content of this article or claim any rights to this article.

References

- Alexiou GA, Varela M, Sfakianos G et al.: Shunting for the treatment of arachnoid cysts in children. *Neurosurgery* 2010; 67: 1632–1636; discussion 1636.
- Basaldella L, Orvieto E, Dei Tos AP et al.: Causes of arachnoid cyst development and expansion. *Neurosurg Focus* 2007; 22: E4.
- Berle M, Wester KG, Ulvik RJ et al.: Arachnoid cysts do not contain cerebrospinal fluid: a comparative chemical analysis of arachnoid cyst fluid and cerebrospinal fluid in adults. *Cerebrospinal Fluid Res* 2010; 7: 8.
- Cameron AD: Psychotic phenomena with migraine and an arachnoid cyst. *Prog Neurol Psychiatry* 2002; 6 (2).
- Fiest KM, Sauro KM, Wiebe S et al.: Prevalence and incidence of epilepsy: a systematic review and meta-analysis of international studies. *Neurology* 2017; 88: 296–303.
- Galassi E, Tognetti F, Gaist G et al.: CT scan and metrizamide CT cisternography in arachnoid cysts of the middle cranial fossa: classification and pathophysiological aspects. *Surg Neurol* 1982; 17: 363–369.
- Gangemi M, Colella G, Magro F et al.: Suprasellar arachnoid cysts: endoscopy versus microsurgical cyst excision and shunting. *Br J Neurosurg* 2007; 21: 276–280.

- Greenberg MS: Handbook of Neurosurgery. 8th ed., Thieme, New York 2016; 252.
- Helland CA, Wester K: Arachnoid cysts in adults: long-term follow-up of patients treated with internal shunts to the subdural compartment. *Surg Neurol* 2006; 66: 56–61; discussion 61.
- Kim SK, Cho BK, Chung YN et al.: Shunt dependency in shunted arachnoid cyst: a reason to avoid shunting. *Pediatr Neurosurg* 2002; 37: 178–185.
- Martínez-Lage JF, Ruíz-Espejo AM, Almagro MJ et al.: CSF overdrainage in shunted intracranial arachnoid cysts: a series and review. *Childs Nerv Syst* 2009; 25: 1061–1069.
- Millichap JG: Temporal lobe arachnoid cyst-attention deficit disorder syndrome: role of the electroencephalogram in diagnosis. *Neurology* 1997; 48: 1435–1439.
- Pradilla G, Jallo G: Arachnoid cysts: case series and review of the literature. *Neurosurg Focus* 2007; 22: E7.
- Puchalska-Niedbał L, Jeżewski D: [Sudden loss of vision as the result of the decompression after the removal of the arachnoid cyst of the temporal region. A case report]. *Ann Acad Med Stetin* 2007; 53 Suppl 1: 80–84; discussion 84.
- Raffel C, McComb JG: To shunt or to fenestrate: which is the best surgical treatment for arachnoid cysts in pediatric patients? *Neurosurgery* 1988; 23: 338–342.
- Roszkowski M, Barszcz S, Jurkiewicz E: Operacje endoskopowe w chorobach mózgu u dzieci. In: Roszkowski M (ed.): Minimalnie inwazyjne techniki w neurochirurgii dziecięcej. EMU, Warszawa 2002: 67–116.
- Stachura K, Czepko R: Wyniki leczenia torbieli pajęczynówki u dorosłych przy zastosowaniu techniki endoskopowej. *Neurol Neurochir Pol* 2006; 40: 391–396.
- Stachura K, Moskała M: Usefulness of silicone elastomer drains in endoscopic treatment of arachnoid cyst – preliminary report. *Videosurg Other Miniinvasive Tech* 2009; 4: 115–120.
- Strojnik T: Different approaches to surgical treatment of arachnoid cysts. *Wien Klin Wochenschr* 2006; 118 Suppl 2: 85–88.
- Vakis AF, Koutentakis DI, Karabetos DA et al.: Psychosis-like syndrome associated with intermittent intracranial hypertension caused by a large arachnoid cyst of the left temporal lobe. *Br J Neurosurg* 2006; 20: 156–159.
- Valença MM, Valença LP, Menezes TL: Computed tomography scan of the head in patients with migraine or tension-type headache. *Arq Neuropsiquiatr* 2002; 60: 542–547.
- Vernooij MW, Ikram MA, Tanghe HL et al.: Incidental findings on brain MRI in the general population. *N Engl J Med* 2007; 357: 1821–1828.
- Weber F, Knopf H: Incidental findings in magnetic resonance imaging of the brains of healthy young men. *J Neurol Sci* 2006; 240: 81–84.
- Wester K: Arachnoid cysts – historical perspectives and controversial aspects. In: Wester K (ed.): Arachnoid Cysts. Epidemiology, Biology, and Neuroimaging. Academic Press, 2018: 3–16.
- Wester K, Hugdahl K: Arachnoid cysts of the left temporal fossa: impaired preoperative cognition and postoperative improvement. *J Neurol Neurosurg Psychiatry* 1995; 59: 293–298.
- Zhang B, Zhang Y, Ma Z: Long-term results of cystoperitoneal shunt placement for the treatment of arachnoid cysts in children. *J Neurosurg Pediatr* 2012; 10: 302–305.